

Clinical Experience Using Ultrasonic-Assisted Wound Treatment

Jeffrey A. Niezgoda, MD, FACEP; Mary M. Verhage, RN, BSN, CWOCN; Dawn Walek, RN; Kathleen M. Nelson, RN, CWCN

The Center for Comprehensive Wound Care and Hyperbaric Medicine, St. Luke's Medical Center, Aurora Health Care & Hyperbaric and Wound Care Associates, Milwaukee, Wisconsin, USA

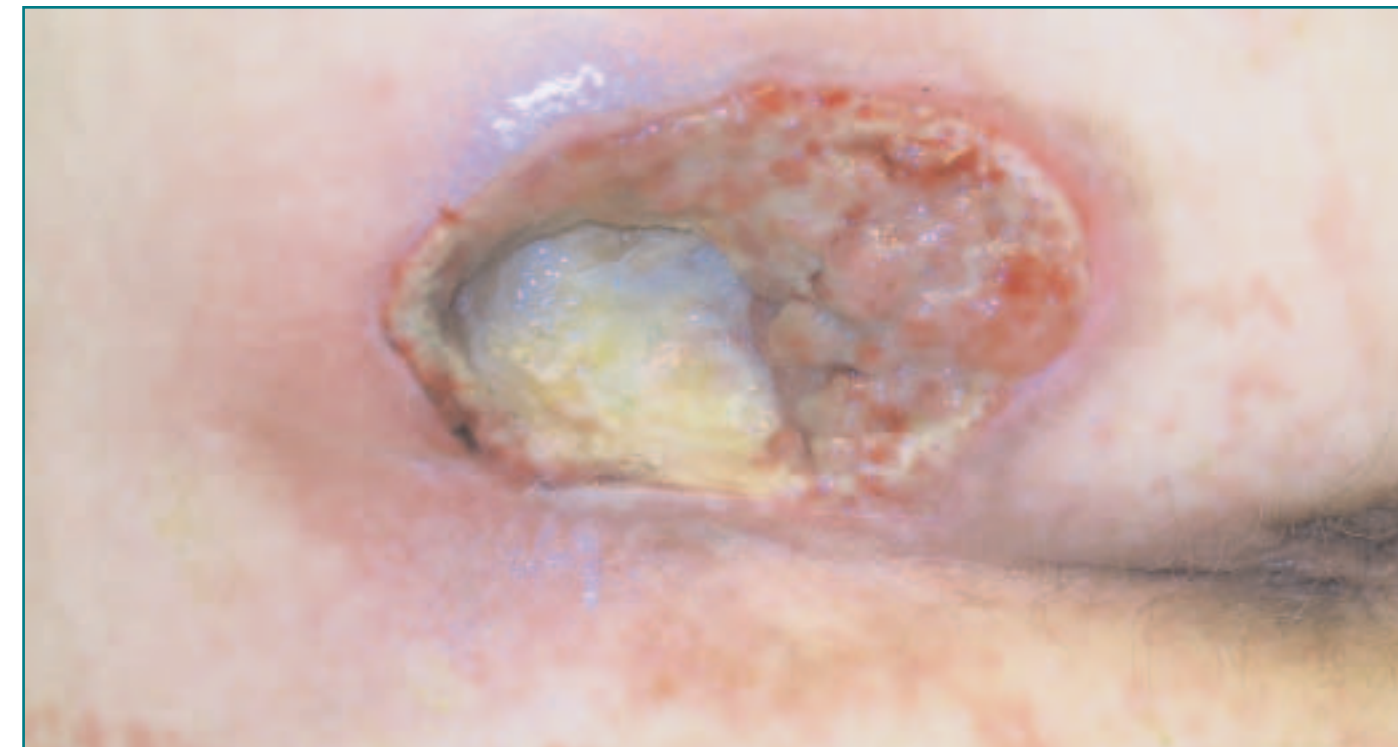Introduction

Low-frequency ultrasonic wound treatment (UAW) is emerging as an alternative method for wound bed preparation and debridement. Low-frequency ultrasound, when applied to the wound bed via a wound treatment solution, allows for deep tissue penetration of ultrasonic vibration and energy. This results in micro-cavitations, which cause bacterial destruction. In vitro wound models have proven highly effective bactericidal effects. The solution also provides a gentle flushing of the wound, cleansing it of fibrin deposits and bacterial growth while preserving the granulation tissue. This debridement technique is particularly useful in deep, tunneling and undermining wounds. UAW is well tolerated by patients due to minimal associated pain. We illustrate the effectiveness of the UAW as a debridement tool and wound treatment technology with a photographic series of a clinical case study.

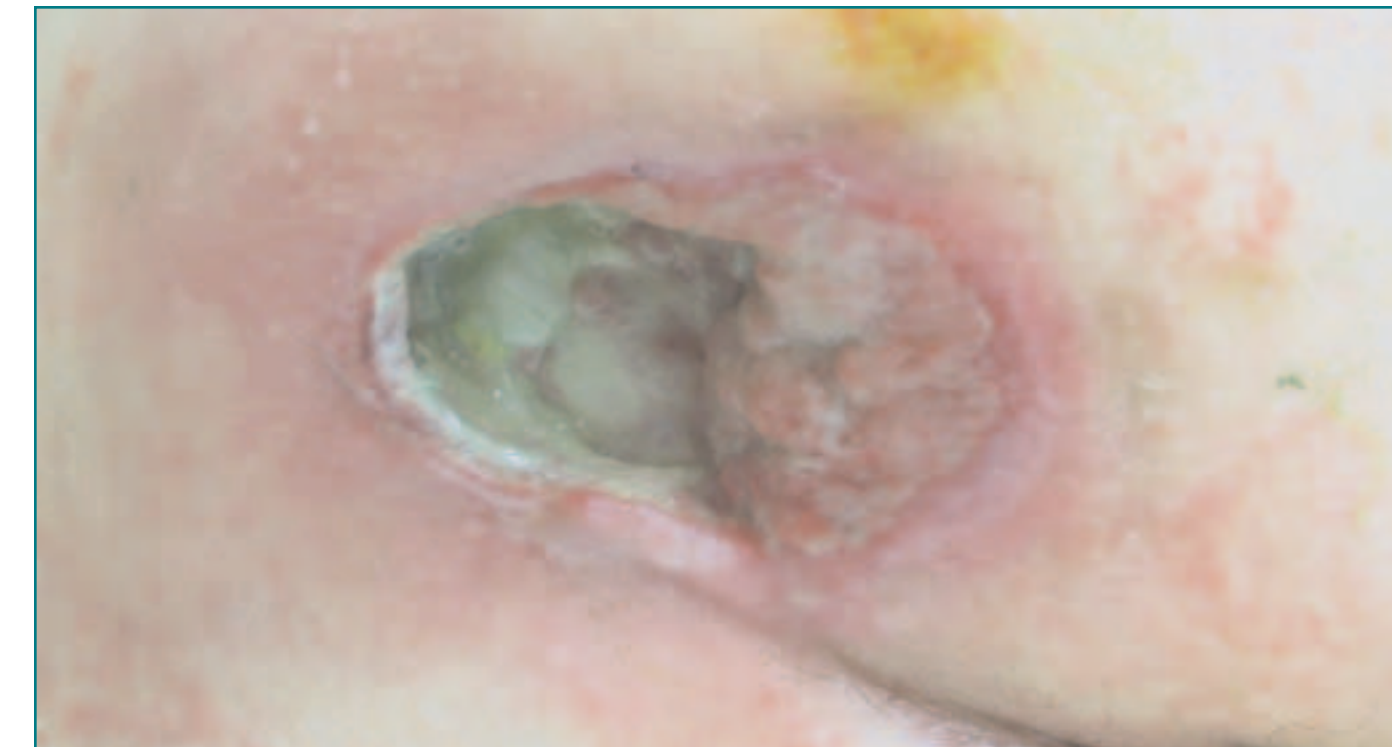Case Study

CK is a 53-year-old female with a 30-year history of multiple sclerosis and has been confined to a wheel chair for several years. She has significant disability with motor and cognitive deficits and diffuse lower extremity weakness and spasm. She was referred to the Center for Comprehensive Wound Care and Hyperbaric Oxygen Therapy for evaluation and treat-

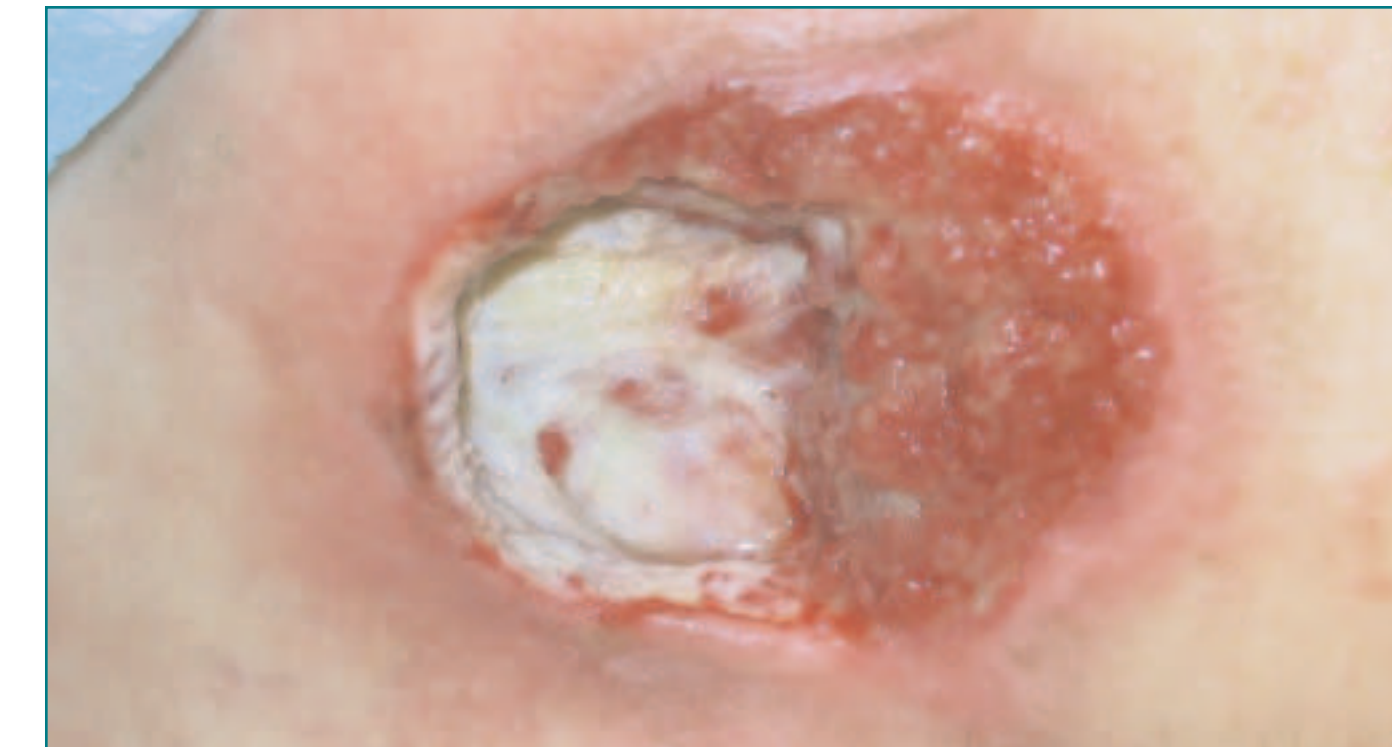ment of a stage III right ischial pressure ulcer that developed during an acute care hospitalization (07/2002). The wound was deteriorating despite offloading efforts including a pressure relief mattress and wheel chair cushion. Following initial consultation, her wound care regimen was modified to include enzymatic debridement and moist wound healing.



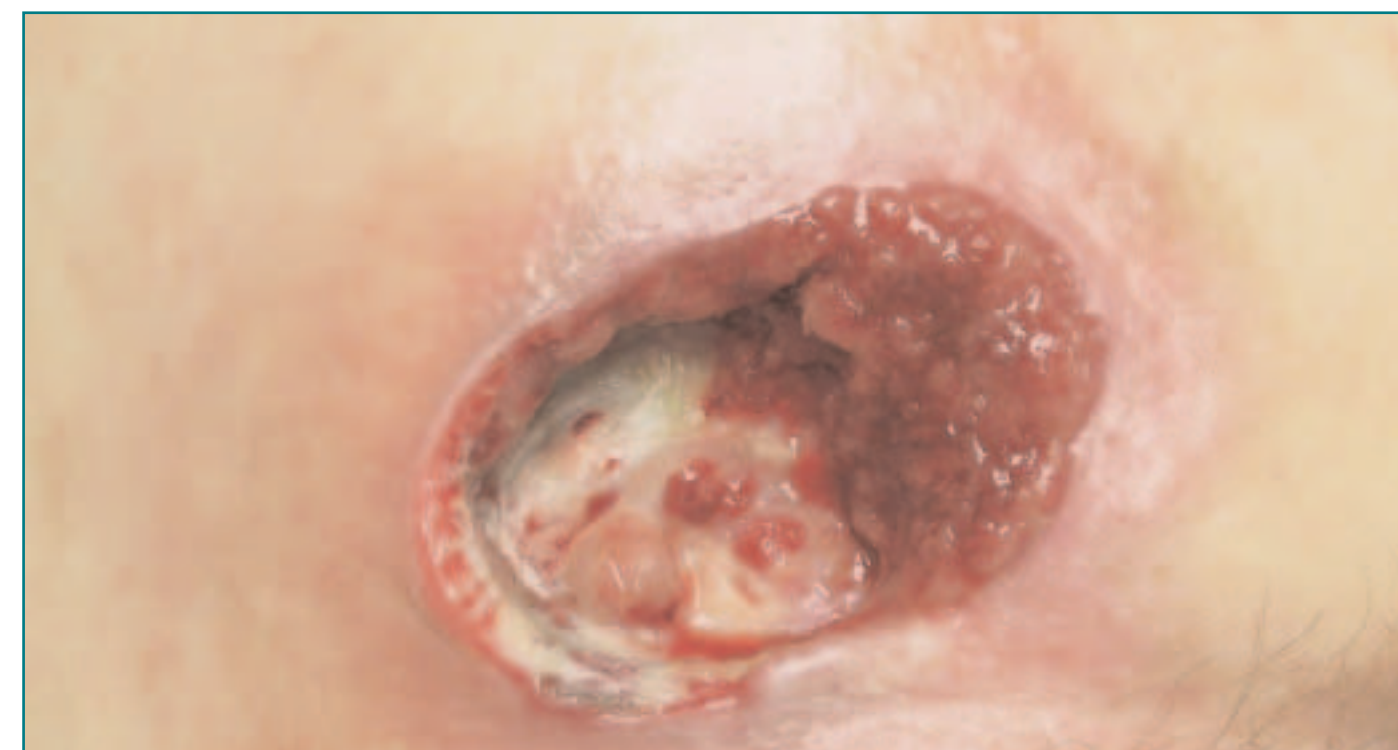Appearance after 4 weeks of enzymatic agent. Persistent densely adherent area of fibrin slough. Sharp debridement preformed. Cultures obtained. Measurement 7.0cm x 5.0cm x 1.9cm



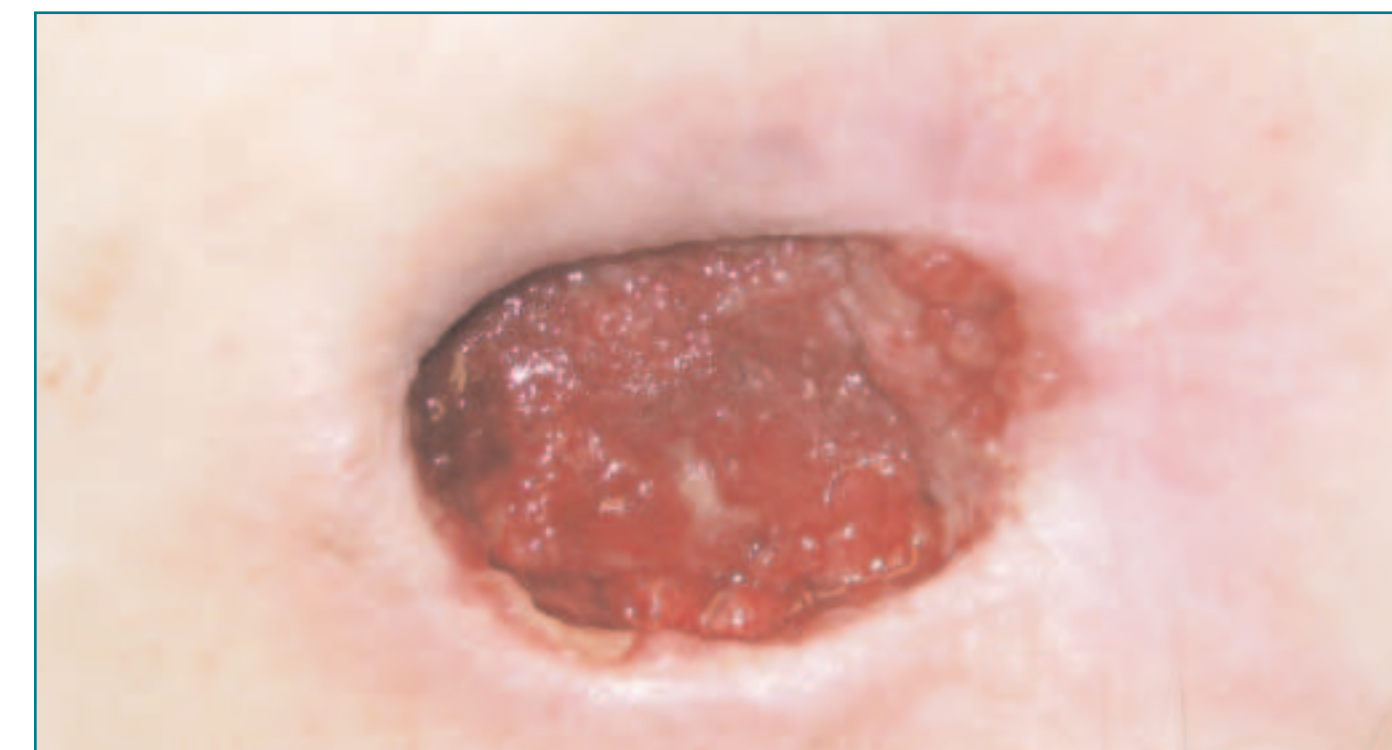
12/06/02: Wound culture positive for Vancomycin Resistant Enterococcus and resistant Pseudomonas Aeruginosa. Ultrasonic Assisted Wound Treatment initiated. Measurement 6.0cm x 3.5cm x 2.2cm



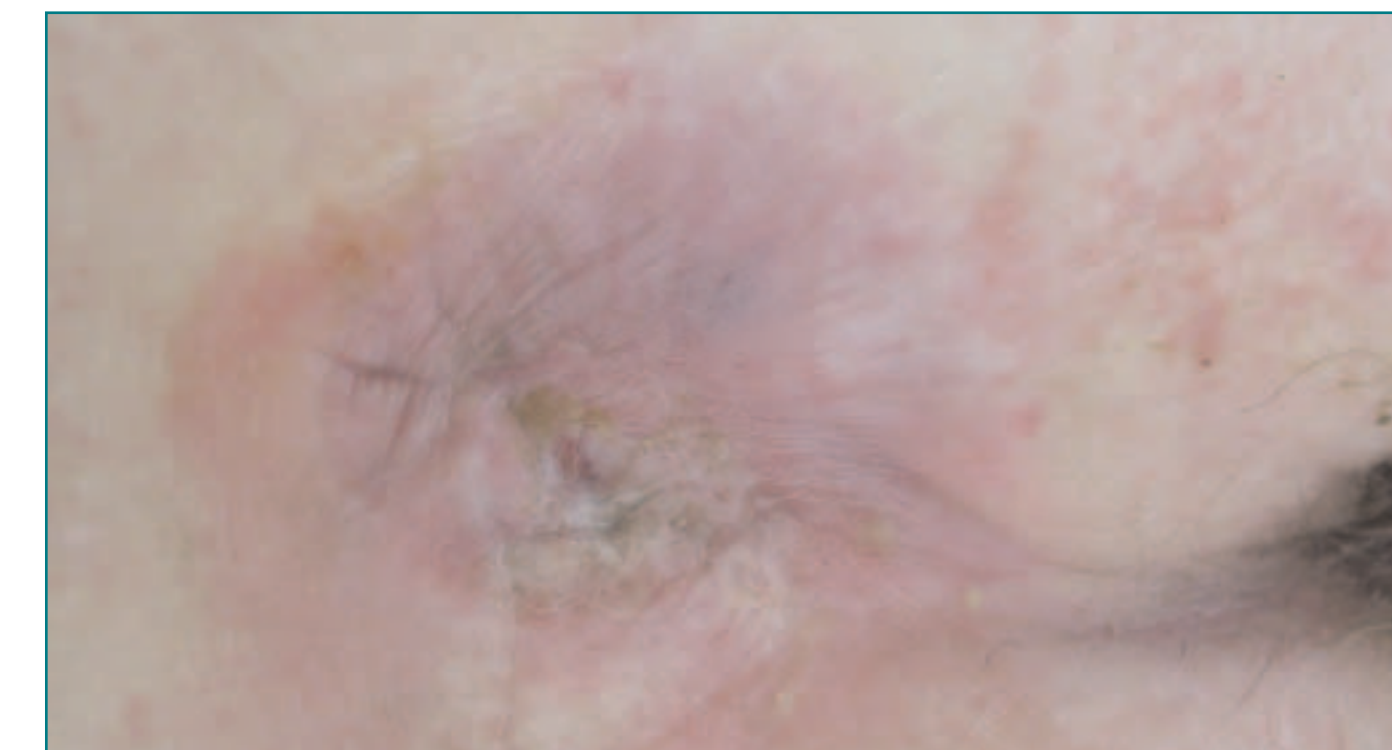
12/06/02: Post-Ultrasonic Assisted Wound Treatment. Quantitative wound culture obtained.



2/13/02: Wound culture negative for VRE or Pseudomonas. Wound again treated with UAW. Pre and post UAW quantitative wound culture obtained. Measurement 5.8cm x 3.4cm x 1.6cm



01/17/03: Wound cultures remain negative for VRE and Pseudomonas.



3/28/03: Wound closed.

Conclusion

This case study illustrates the effectiveness of Ultrasonic Assisted Wound Treatment in the management of compromised wounds. UAW is an efficient debridement tool for wounds with dense fibrin slough. In addition, UAW has impressive bactericidal effects. UAW therapy has demonstrated the elimination of resistant bacterial organisms, including VRE and Pseudomonas, in both in vitro and in vivo settings. Low frequency ultrasonic wound treatment is an advanced technology that is rapidly gaining acceptance as an alternative method to surgical and sharp debridement techniques. This advanced wound care technology has the potential to revolutionize wound care practice by enhancing clinical outcomes while maintaining cost efficiency.